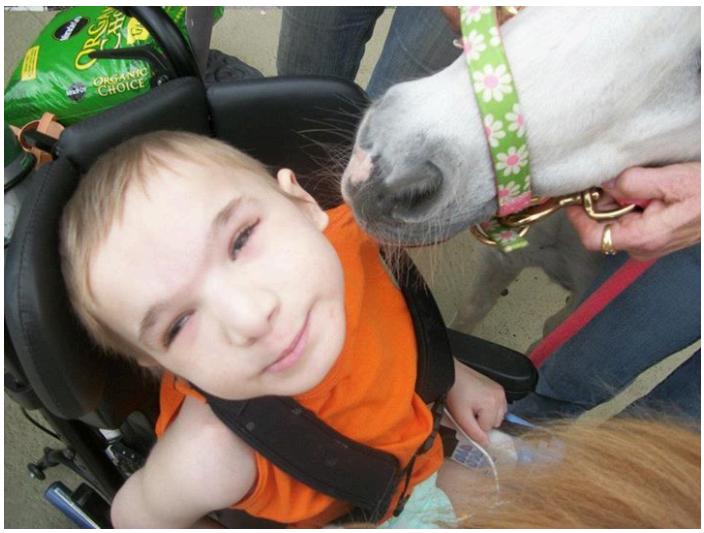

Jonathan was born in 2001 and was not prenatally diagnosed (full trisomy 13). He lives in the United States. Participation in the TRIS project began in 2007.

Mother was 39 and father was 36 years old at the time of conception. Child with rare trisomy was sixth of six pregnancies (gravida, 6; para, 6). No siblings have been diagnosed with a genetic, terminal, medical, or neurological condition.

Birth Information

Male infant was delivered via spontaneous vaginal birth after 15 hours of labor at 39 weeks gestation. Infant was delivered at home by a midwife. Infant presented in a breech position. Infant was diagnosed with full trisomy 13 at 2 weeks of age through blood work.

Infant was born weighing 3370 grams and 53 centimeters in April 2001. APGAR were not done as the midwife focused on providing oxygen and monitoring breathing. Infant was blue at birth.

At birth, infant presented with low-set ears and polydactyly of both hands. Infant also presented with the following medical issues: respiratory distress, feeding difficulties, and jaundice.

Infant was transferred to a neonatal intensive care unit (NICU) at local hospital for the majority of post-birth care. He remained on unit for 26 days. Infant was in an oxygen tent for three days and then changed to a nasal cannula for supplemental oxygen. A pulse oximeter was used to monitor saturation levels prior to discharge. Infant was fed via gavage and intravenously (IV). An audiology exam, echocardiogram, ophthalmology exam, ultrasound, and x-ray series were performed in the post-birth care unit.

Surgeries

Child underwent surgery for a gastrostomy tube and nissen fundoplication at 42 months. A vesicostomy was performed at 97 months and vesicostomy repair at 122 months. Three surgeries were needed to address a perforated bowel. Surgeries were completed when child was 121 and 122 months of age.

Cardiac

Child has not been diagnosed with any heart defects.

Respiratory

Child requires supplemental oxygen and Albuterol for management of central apnea. At 128 months, child also required use of a bi-level positive airway pressure (Bi-PAP) device. TRIS Follow-up Surveys indicate child experienced respiratory illnesses each year since beginning participation in the project in 2007. Treatment with antibiotics and nebulizer treatments, steroids and other medications have been successfully used.

Since March 2014, child has experienced increased apnea spells. Results from a sleep study in April 2014 confirmed sleep apnea. Child was prescribed use of a continuous, positive airway pressure device to address this condition.

Neurological

Child experienced infantile spasms from 5 to 36 months of age. This condition was treated with Dilantin and Phenobarbital. Phenobarbital was effective.

Child started experiencing petit mal, grand mal, and mixed type seizures at 18 months. At 79 months, child was still experiencing petit mal seizures. Phenobarbital, Topomax, Keppra, and Trileptal have been prescribed for control of seizures. Phenobarbital was discontinued at 30 months and replaced with Trileptal and Keppra. Topomax was added at about 65 months.

At 95, 111, and 128 months, child experienced tonic-clonic, myoclonic, and simple partial seizures. At 95 months, the child was prescribed Trileptal and Klonipin. At 111 months, he was prescribed Trileptal, Diazepam, Clonazipam, and Banzel. At 128 months, child was prescribed Trileptal, Keppra, Banzel, and Clonazepam. At 145 months, child experienced tonic-clonic seizures and was prescribed Trileptal, Keppra, Banzel, Topomax, Clonazepam, and Diazepam. At 154 months, child was prescribed Ativan PRN for breakthrough seizures. All medications were reported to make the child very sleepy and produced apneic spells.

Renal

Child has been diagnosed with a polycystic, hypoplastic right kidney. This condition is monitored by ultrasound every six months. At 95 months, child was diagnosed with kidney failure in both kidneys. In addition, renal failure was noted due to extreme dehydration during a bout with pancreatitis at 85 months of age.

At 92 months, child was catheterized. A vesicostomy was done at 97 months (surgical opening in the bladder to the outside of the body for urine to drain, preventing urinary tract infection or damage to the kidneys); vesicostomy repair was done at 122 months. Catheterization was not needed after the vesicostomy.

Endocrine

Child was diagnosed with hypothyroidism at 66 months. Child is treated with synthroid, (50 mcg). Medication was stopped at 121 months because it was reducing the effectiveness of Topomax to control child's seizures.

Gastrointestinal

At the age of two months, infant started experiencing periods of reflux and constipation. Glycerin suppositories and Babylax enemas were used to treat constipation. Miralax was started at approximately 36 months of age. To treat reflux, Prevacid, and Zantac were prescribed but neither medication was effective. Mother reports using positioning to address reflux. Child was kept in an upright, sitting position for an hour after being fed.

Child underwent surgery for a gastrostomy tube and nissen fundoplication at 42 months. Between 111 and 128 months, child was prescribed Miralax for constipation. The medication was not effective. At 145 months, Eryped and Prevacid were prescribed for continuing reflux. Neither medication was effective. Child was diagnosed with a stomach ulcer from the g-tube at 50 months and was prescribed Carafate. At 121 months, child was successfully treated for an obstructed bowel that led to a perforation.

Nutrition

Child was fed breast milk from a bottle when discharged. Infant continued to receive formula at home. Child began eating pureed foods at 18 months. A gastronomy tube was placed at 42 months for failure to thrive. Mother reports it would take an hour to feed child three ounces of solid food due to child's reverse swallow (tongue thrust). When given a bottle, approximately a third to a fourth "dribbled out". In addition, child would spit out seizure medication so proper dosage was not received orally. Child continued to receive formula from a bottle and solid foods by mouth (one meal a day) until 88 months of age.

The change to all g-tube feedings at 88 months occurred due to aspiration. Child had aspiration pneumonia three times in approximately six months. During this time, mother notes when child drank from a bottle there was increased choking even with more upright positioning. Difficulties were also observed with solid food.

Beginning at 126 months, child received nutrition by jejunostomy tube. G-tube was used for all medications and to vent after feedings. Due to gastroparesis, child could no longer be fed through the stomach. A j-tube is used for continuous feeds. Child had a PICC line from 121 to 126 months for IV feedings of total parenteral nutrition (TPN) and lipids due to perforated bowel that required three bowel surgeries. G-tube feedings were unsuccessful due to a lack of stomach emptying.

Orthopedic

At 79 months, child was noted to use a manual wheelchair, specialized bed, and bath seat. Child has used orthopedic leg/ankle braces (AFOs) for treatment of drop foot and femoral anteversion (in-toeing) since 90 months of age.

Since 146 months of age, child has resting hand splints due to contractures of the fingers.

Oral health

Child's first dental visit was at four years of age. Child has been diagnosed with enamel abfraction (loss of enamel at the gum line). Child visits the dentist every six months. At 145 months, the child needed additional dental cleanings due to excessive plaque. Child was also diagnosed with impacted molars at 140 months, which have now both erupted through hard palate. Mother states that this will not be treated unless they become infected. It would be too risky to perform surgery to remove the molars since that would expose the sinuses which could be damaged and cause additional complications.

Vision

Child was diagnosed with cataracts and cortical visual impairment at 11 months of age. Conditions are monitored biannually.

Auditory

Child has not experienced ear infections or been diagnosed with hearing loss.

Immunizations

Child was immunized based on recommended immunization schedule. Child received Diphtheria, Tetanus, and Pertussis (DPT), Haemophilus influenza type B (HIB), Hepatitis B series, Inactive poliovirus, influenza, Measles, Mumps, and Rubella (MMR) and Varicella. No adverse reactions were reported after any immunization.

Current Education and Therapy Services

Prior to 36 months, child received in home early intervention services including occupational therapy, physical therapy, and speech and language therapy.

At 79 months, the child received 30 minutes of occupational therapy, 45 minutes of physical therapy, and 90 minutes of speech therapy per week at home. At 95 months the child received occupational therapy and physical therapy services. No therapy or related services were recorded after 95 months. Child has always been homeschooled (mother is a certified special education teacher).

Developmental milestones

At initial survey completion at 79 months, child had attained skills in the 3-7 month range (indicates need by vocalizing and rolls from stomach to back or back to stomach) with a few skills extending into the 9-12 month range (show preference for familiar adults and prefers such as main caregiver).

Currently, mother notes that child's skills have diminished over the years due to progression of his genetic condition, seizure activity and "crashing" in the operating room during gastrostomy tube surgery at 42 months of age. Child has lost much of his abilities especially motor skills.

Child used to hold and transfer toys from hand to hand, and hand to mouth but is no longer is able to hold objects. He also cannot roll over anymore. It is necessary to turn child in his bed every two to three hours.

Communication skills are still in the "baby phase" of crying, cooing, grunting, and grimacing to indicate wants and needs. Child says two words (“mom” and “yeah”) and communicates through smiles and laughter. Cognitive development has regressed. Child is noted to have some problem solving skills. For example, - a stuffed monkey that plays music when its stomach is pressed is placed in the same place in child’s bed. Child will intentionally punch it when he wants to hear the music. Socially, child still responds to family members and regular nurses. Mother notes when someone has been gone for a few days, child shows much joy when he hears their voice and receives kisses and pats.

For more information on the Tracking Rare Incidence Syndromes (TRIS) project:

Homepage: http://web.coehs.siu.edu/grants/tris/

Case studies page: http://web.coehs.siu.edu/Grants/TRIS/casestudies.html

Facebook page: https://www.facebook.com/TRIS.Trisomy.project